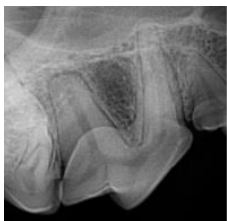

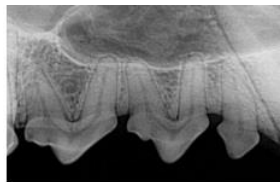Canine Full-Mouth Radiographic Sample Series
August 4, 2018; Signalment, Mixed-breed, intact male, estimated 2 years old

Right

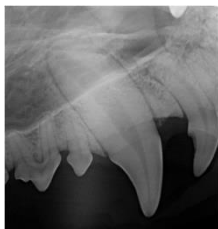Left



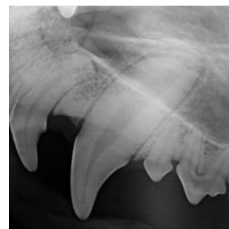
108



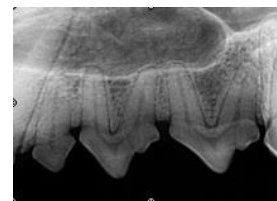
105,106,107



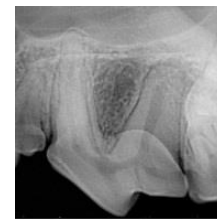Lateral 104



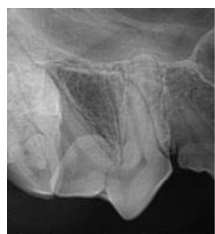Lateral 204



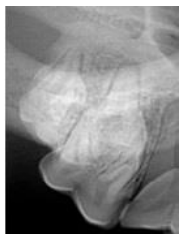
205,206,207



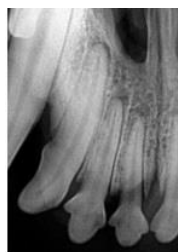
208



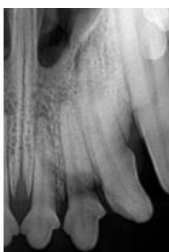108 root separation



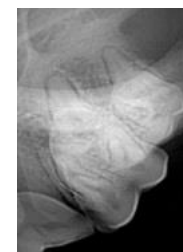
109-110



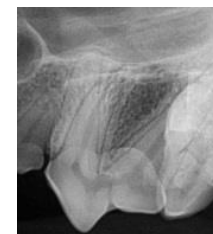101,102,103



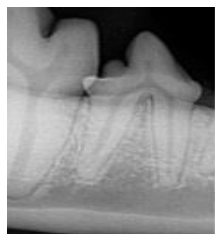201,202,203



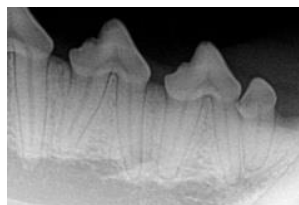
209,210



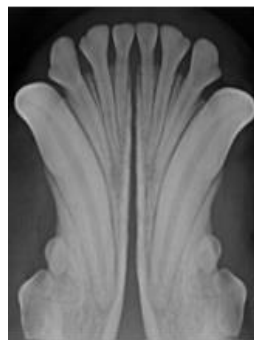208 root separation



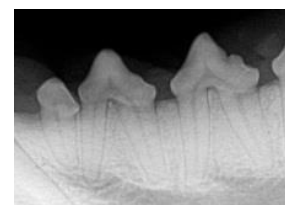
408



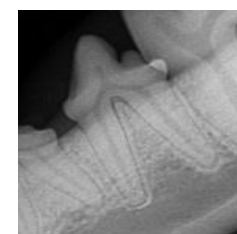
405,406,407



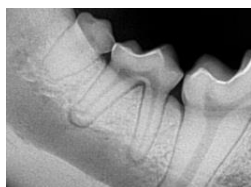301,302,303
401,402,403



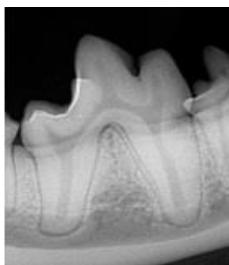
305,306,307



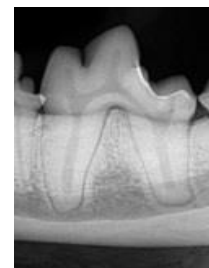
308



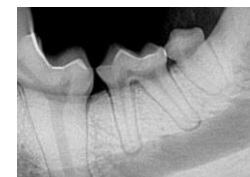410,411



409



309



310,311