

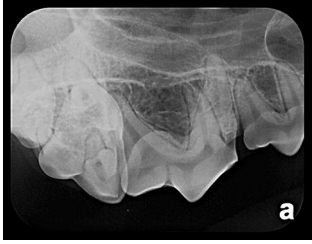Canine Full-Mouth Radiographic Series

December 4, 2009; Signalment: cadaver, mixed-breed, intact male, 1.5 years old

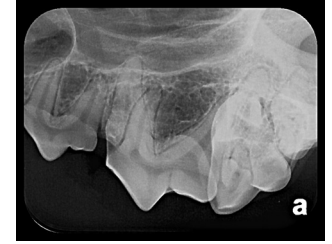Right

Rostral

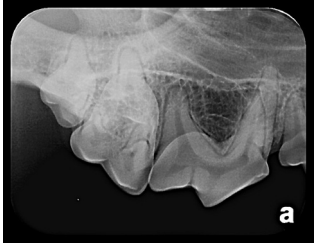Left



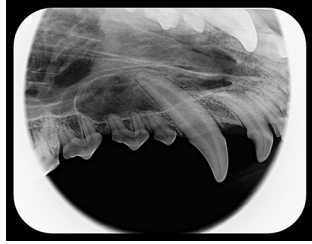108 mesial
root separation



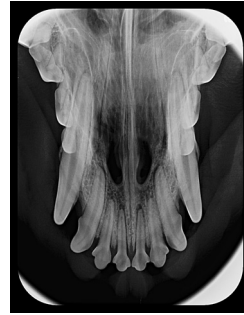208 mesial
root separation



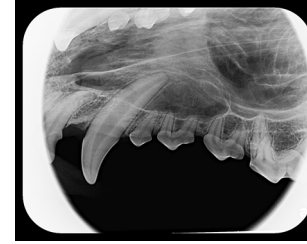Intraoral bisecting angle
108, 109, 110



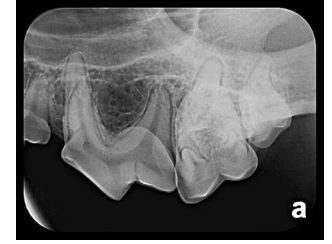Intraoral bisecting angle
104, 105, 106, 107



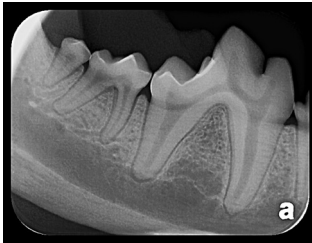Intraoral bisecting angle
101, 102, 103, 201, 202, 203



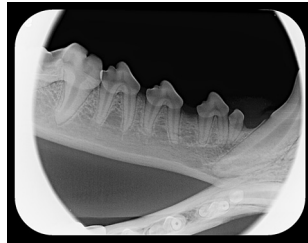
Intraoral bisecting angle
204, 205, 206, 207



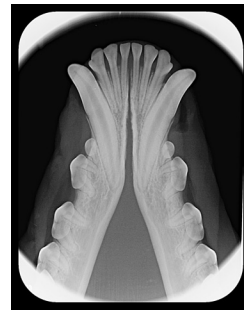Intraoral bisecting angle
208, 209, 210



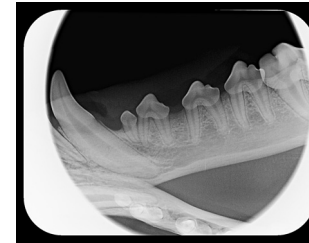
Intraoral parallel
409, 410, 411



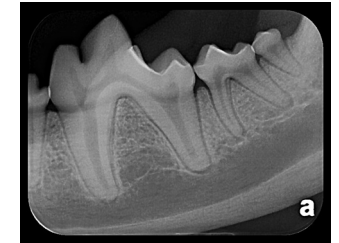Intraoral bisecting angle
405, 406, 407, 408



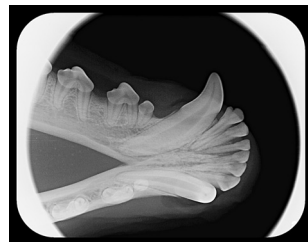Intraoral bisecting angle
301, 302, 303, 304,
401, 402, 403, 404



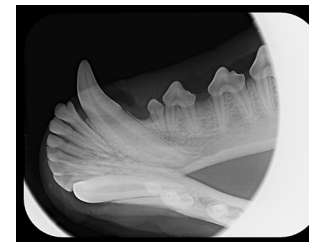
Intraoral bisecting angle
305, 306, 307, 308



Intraoral parallel
309, 310, 311



Intraoral bisecting angle
404



Intraoral bisecting angle
304