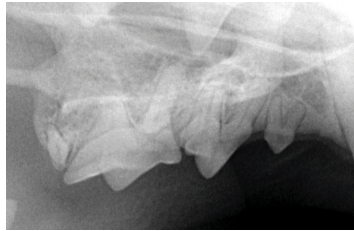

Cadaver
Species: Feline
Breed: DSH
Age: unknown

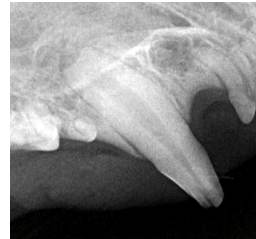
March 2015

Full-mouth dental cat survey

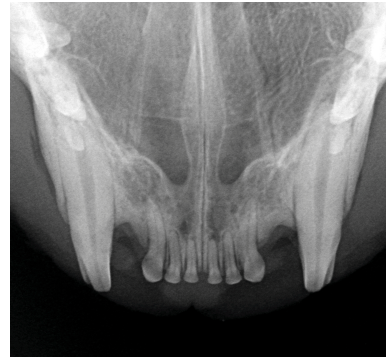
RIGHT



106, 107, 108, 109
Extraoral, Bisecting angle

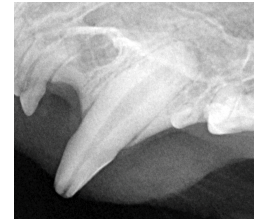

104
Lateral-oblique
Bisecting angle
Complicated crown
fracture

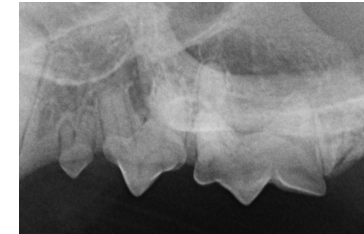

101, 102, 103, 201, 202, 203
Bisecting angle

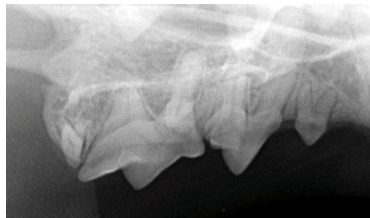LEFT



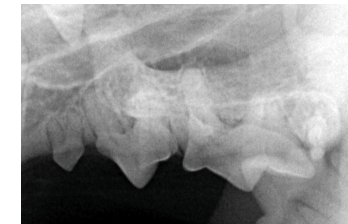
204
Lateral-oblique
Bisecting angle
Complicated crown
fracture



206, 207, 208, 209
Extraoral, Bisecting angle



108
Extraoral, Bisecting angle
Isolation of the mesial root
of the fourth premolar from
the palatal root



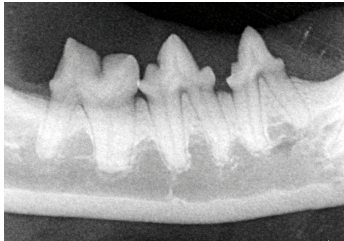
208
Extraoral, Bisecting angle
Isolation of the mesial root
of the fourth premolar from
the palatal root

Cadaver
Species: Feline
Breed: DSH
Age: unknown

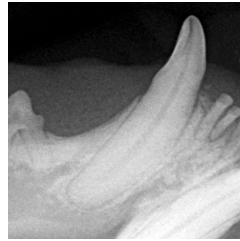
March 2015

Full-mouth dental cat survey

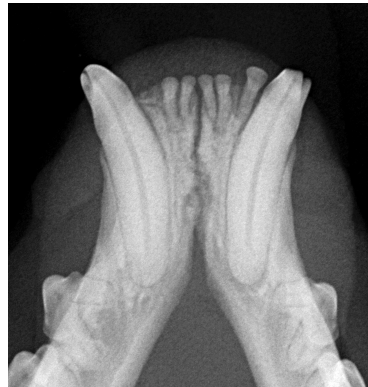RIGHT



407, 408, 409
Parallel angle

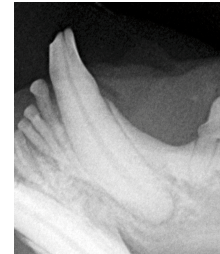


404 Lateral
Bisecting angle
Uncomplicated
crown fracture

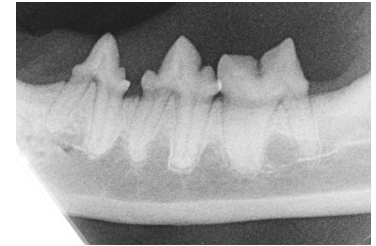


401, 402, 403, 301, 302, 303
Bisecting angle

LEFT



304 Lateral
Bisecting angle
Uncomplicated
crown fracture



307, 308, 309
Parallel angle