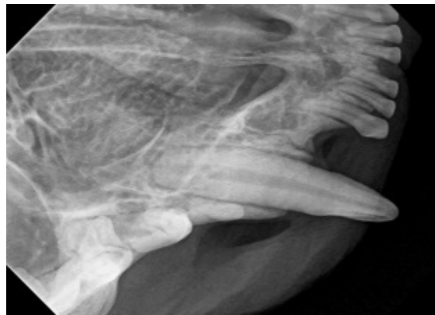

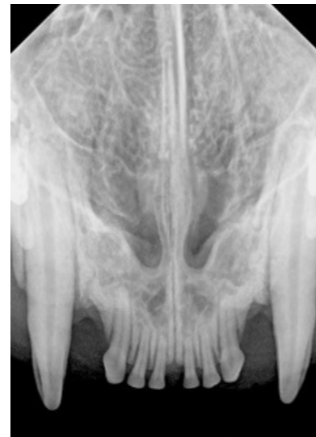
Feline full-mouth radiographic series
Cadaver, unknown age and sex
10/27/2014

Patient right

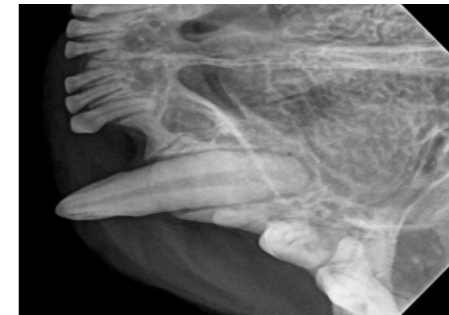Patient left



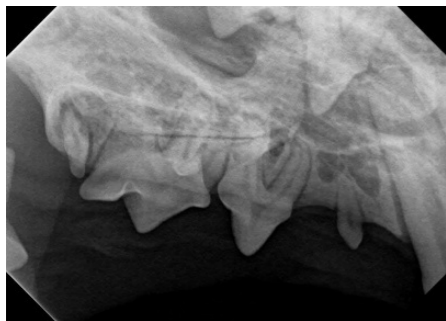104



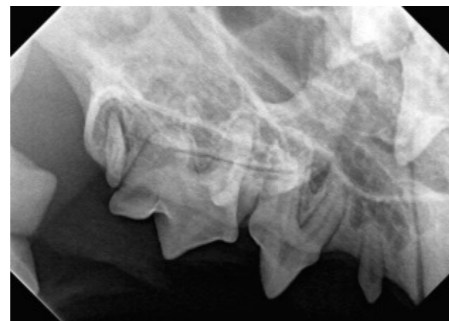103-203



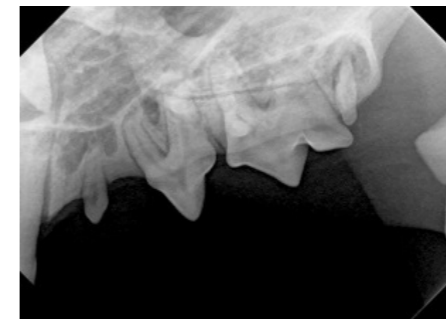204



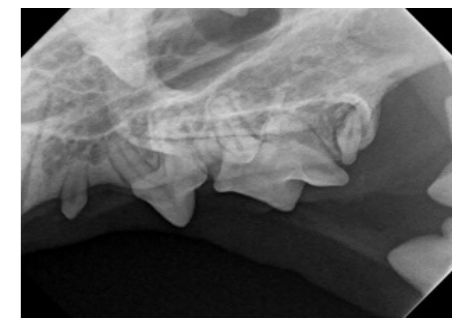mesiodistal separation 108
107 distal root
extra-oral



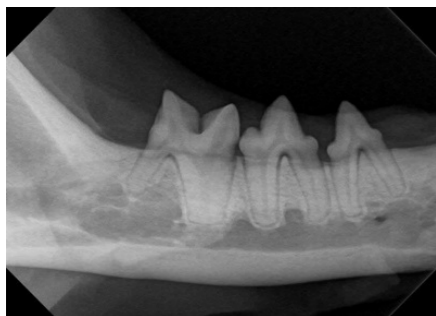106-109
extra-oral



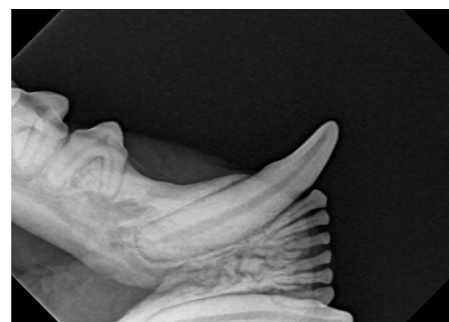
206-209
extraoral



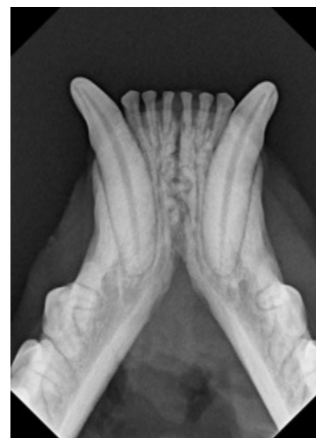mesiodistal separation 208
207 distal root
extra-oral



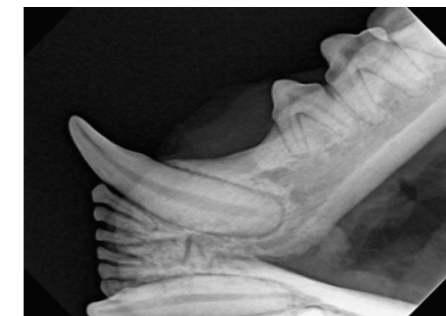407-409



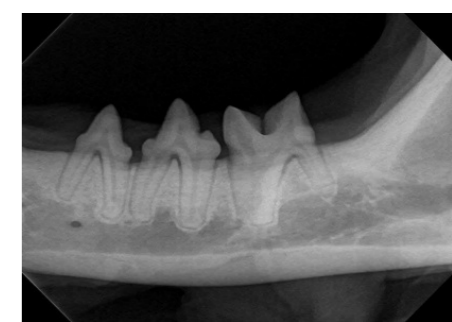
404



303-403



304



307-309