

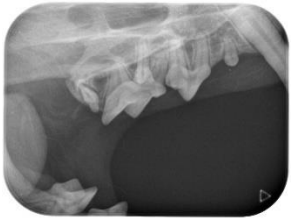Cadaver
Species: Feline
Breed: Domestic
Age: Unknown

May 2019

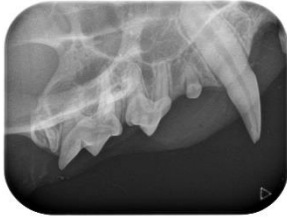Feline Full Mouth Radiographic Series

Right

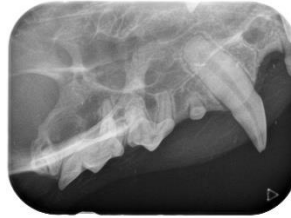Left



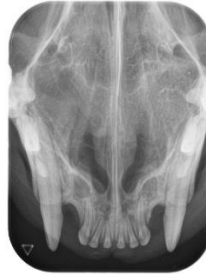108 Intraoral Near Parallel Technique mesial root separation



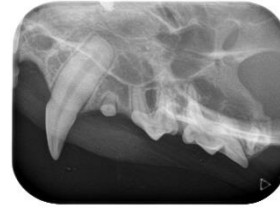106,107,108,109 Lateral



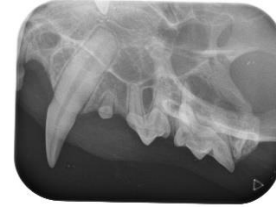104 Lateral



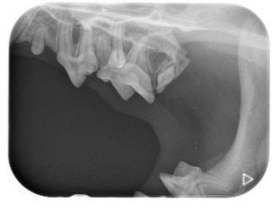101, 102, 103, 104, 201, 202, 203, 204 Occlusal



204 Lateral

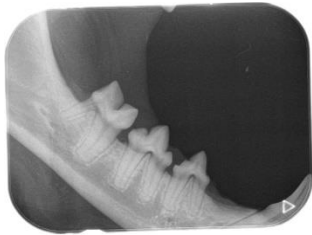


206, 207, 208, 209 Lateral.

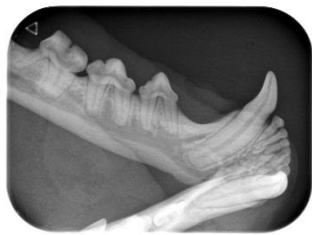

208 Intraoral Near Parallel Technique mesial root separation

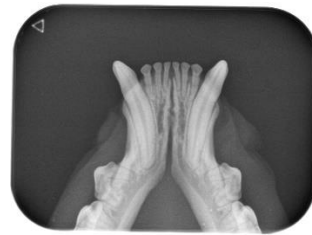Rostral



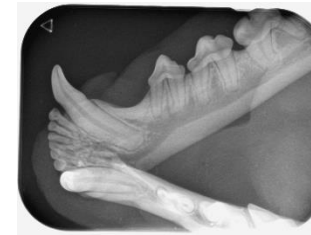
407,408,409 Lateral



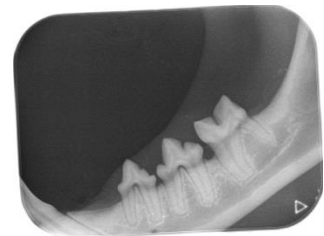
404 Lateral



301, 302, 303, 304, 401, 402, 403, 404 Occlusal



304 Lateral



307, 308, 309 Lateral