

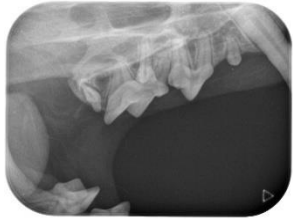Cadaver
Species: Feline
Breed: Domestic
Age: Unknown

May 2019

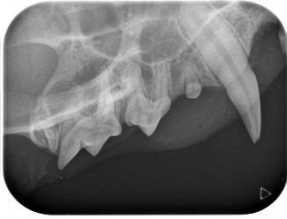Feline Full Mouth Radiographic Series

Right

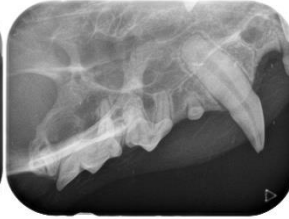Left



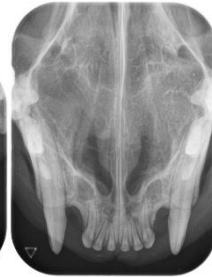
Intraoral Near Parallel Technique - mesial root separation 108



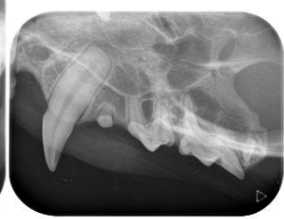Intraoral Near Parallel Technique 106,107,108,109



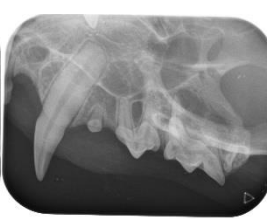Intraoral Bisecting Angle 104



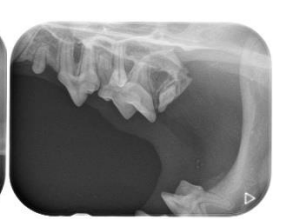Intraoral Bisecting Angle Occlusal 101-104, 201-204



Intraoral Bisecting Angle 204

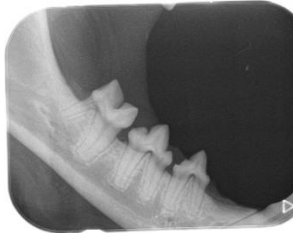

Intraoral Near Parallel Technique 206,207,208,209

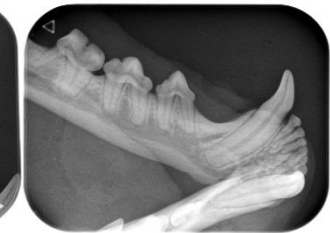

Intraoral Near Parallel Technique - mesial root separation 208

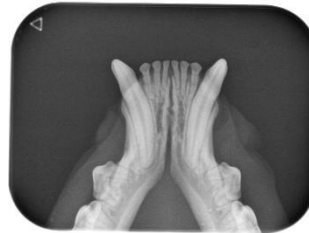Rostral



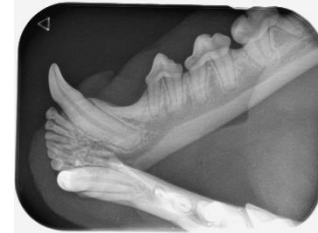Intraoral Parallel Technique 407,408,409



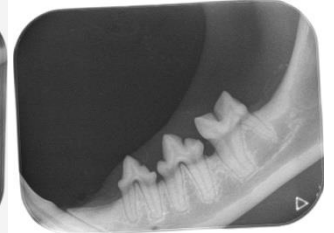
Intraoral Bisecting Angle 404



Intraoral Bisecting Angle Occlusal view 301-304,401-404



Intraoral Bisecting Angle 304



Intraoral Parallel Technique 307,308,309