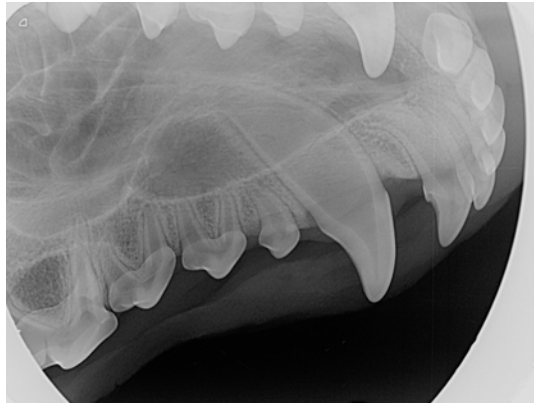


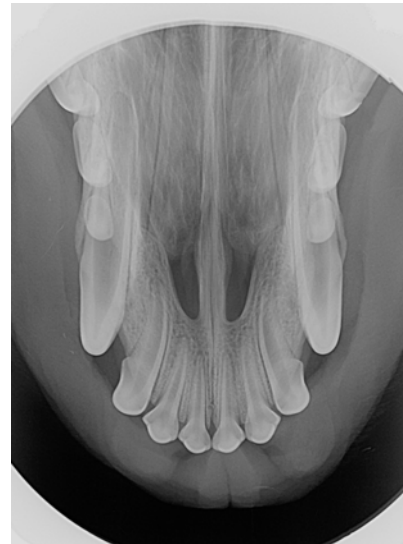
# Canine Full-Mouth Radiograph Set

Cadaver  
Unknown Age Mixed-Breed  
June 2015



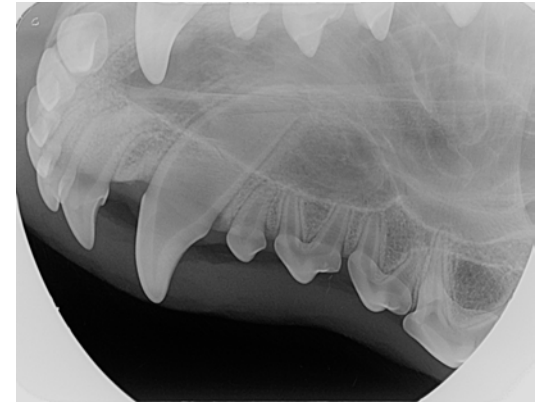
104

Right



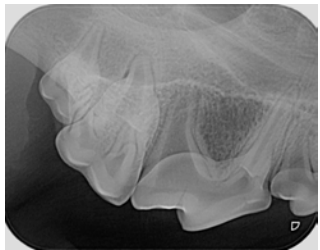
101, 102, 103, 201, 202, 203

Maxilla

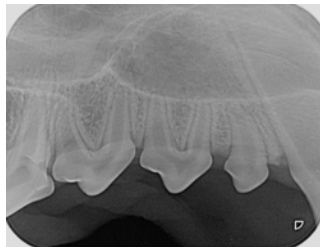


204

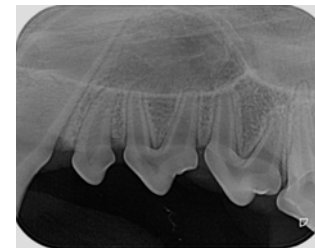
Left



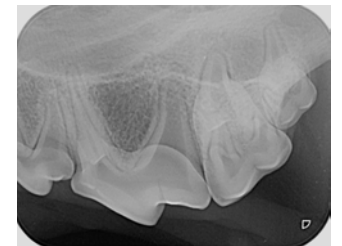
108, 109, 110



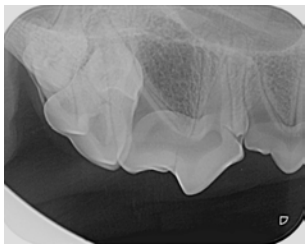
105, 106, 107



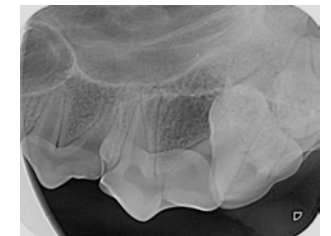205, 206, 207



208, 209, 210



Mesiolateral oblique for  
separation of 108 mesial roots

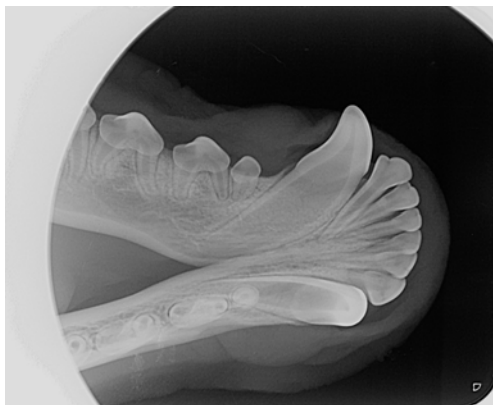


Mesiolateral oblique for  
separation of 208 mesial roots

# Canine Full-Mouth Radiograph Set

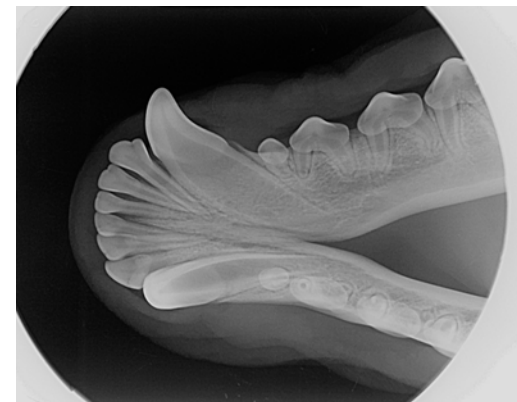
Cadaver  
Unknown Age Mixed-Breed  
June 2015

## Mandible



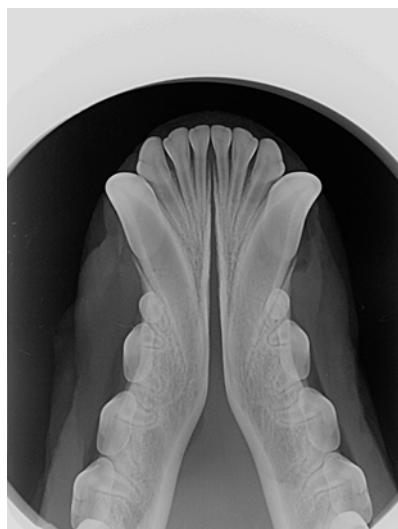
Right

404

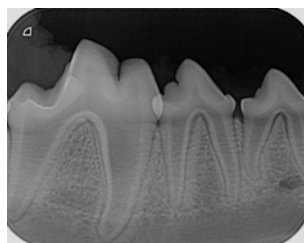


304

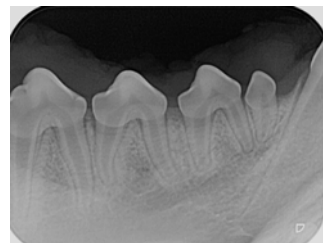
Left



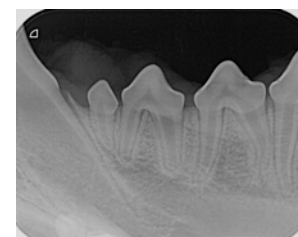301, 302, 303, 401, 402, 403



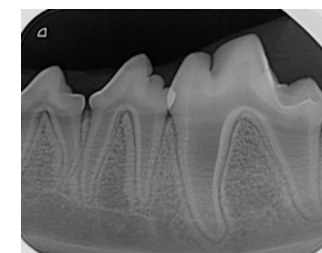
408



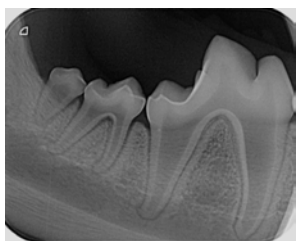
405, 406, 407



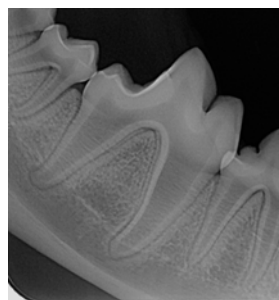
305, 306, 307



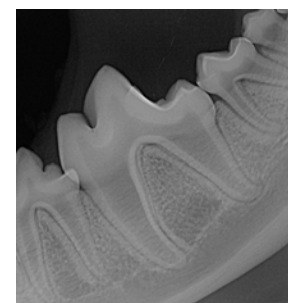
308



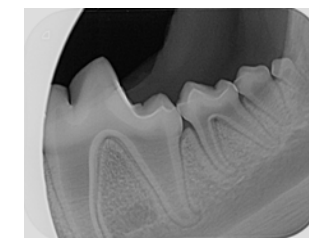
410, 411



409



309



310, 311, SN tooth