

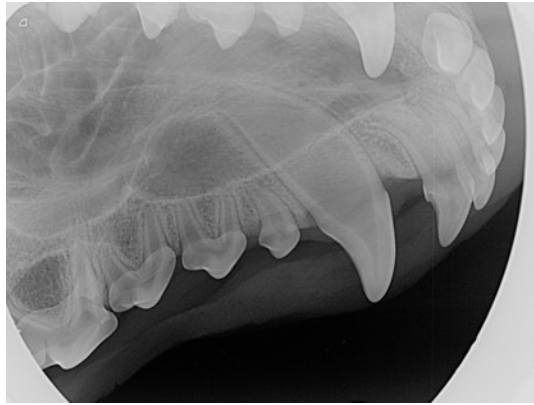
# Canine Full-Mouth Radiograph Set

Cadaver

Unknown Age Mixed---Breed

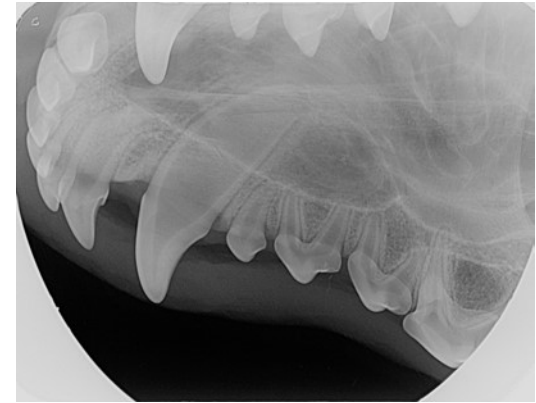
June 2015

## Maxilla



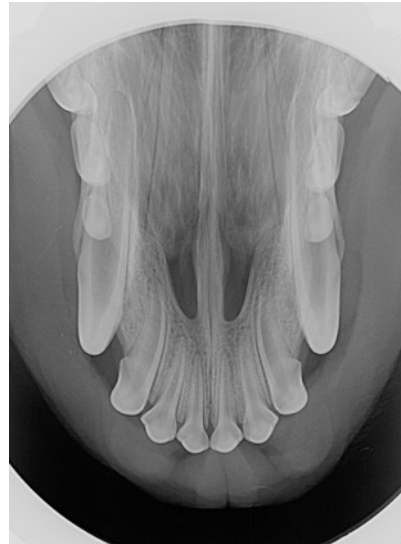
104 Lateral

Right



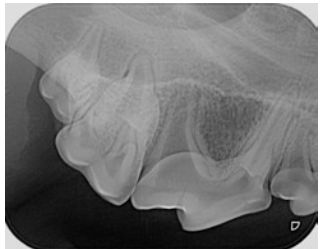
204 Lateral

Left

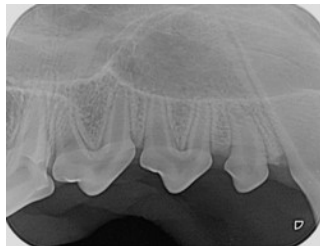


101, 102, 103, 104, 201, 202, 203, 204

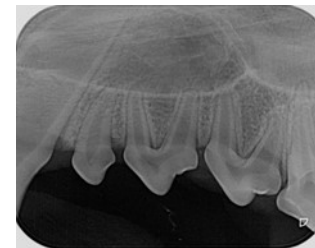Occlusal



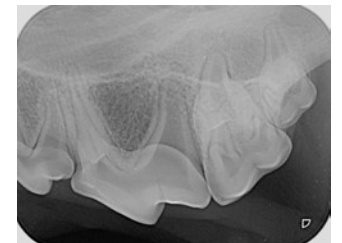
108, 109, 110 Lateral



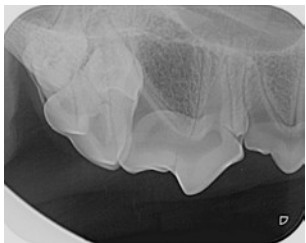
105, 106, 107 Lateral



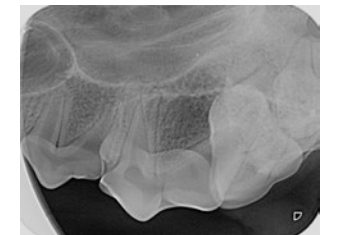205, 206, 207 Lateral



208, 209, 210 Lateral



Mesiolateral oblique for  
Separation of 108 mesial roots



Mesiolateral oblique for  
Separation of 208 mesial roots

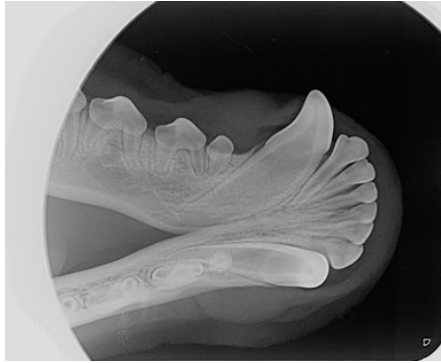
# Canine Full-Mouth Radiograph Set

Cadaver

Unknown Age Mixed---Breed

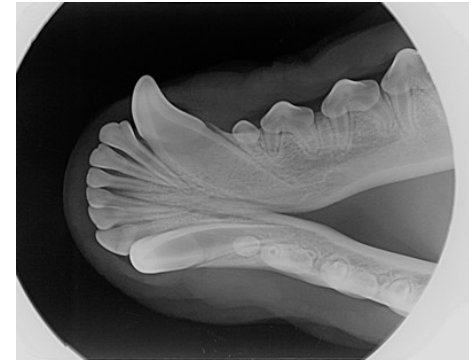
June 2015

Mandible



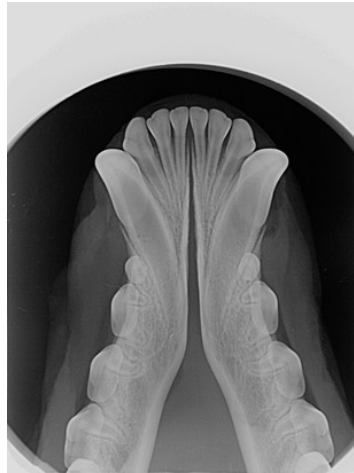
404 Lateral

Right



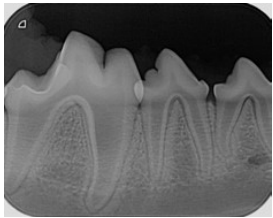
304 Lateral

Left

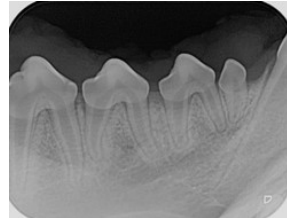


301, 302, 303, 304, 401, 402, 403, 404

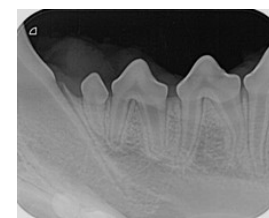Occlusal



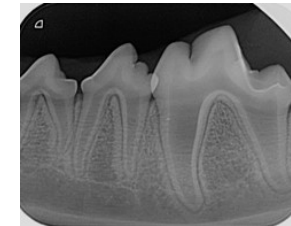
408 Lateral



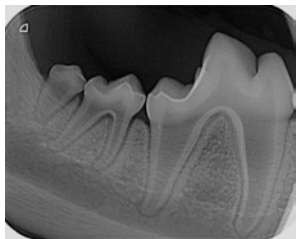
405, 406, 407 Lateral



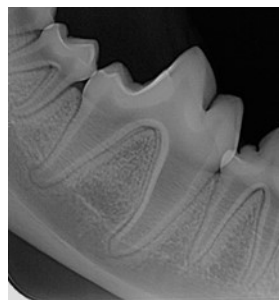
305, 306, 307 Lateral



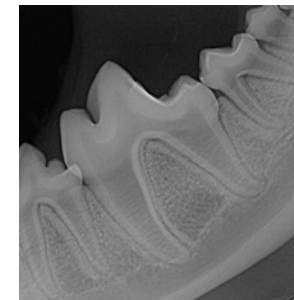
308 Lateral



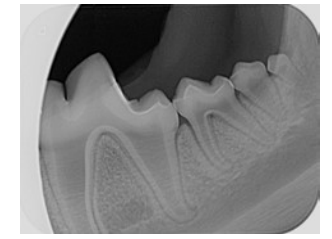
410, 411 Lateral



409 Lateral



309 Lateral



310, 311 Lateral